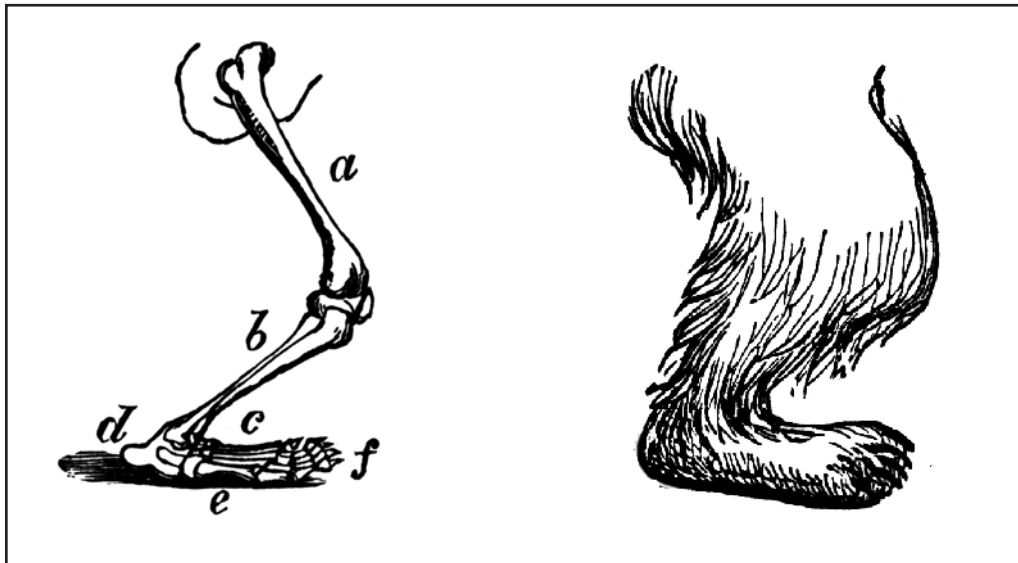
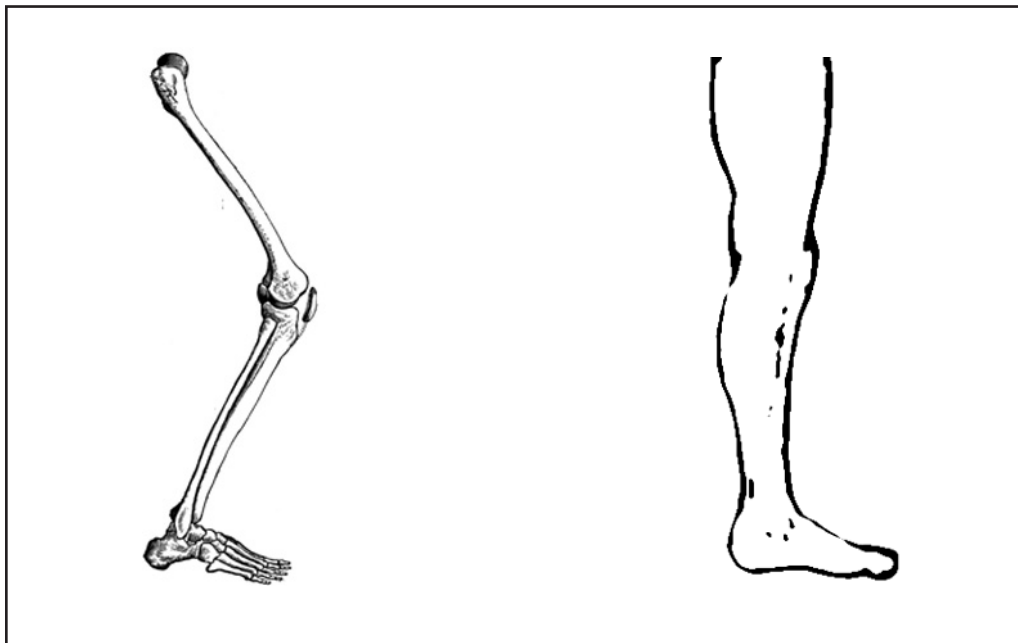


## Comparing Bear and Human Anatomy



The anatomy of a bear's leg.  
a. femur (thigh) b. tibia (leg) c. tarsus and metatarsus (foot)  
d. calx (heel) e. planta (sole) f. digits (toes)



The anatomy of a human leg.  
Label the bones of the human leg.  
Compare the skeletal views and the external views of the bear and human legs.